

Patient: KOLENOVIC^ELEZ Page: 1 of 8



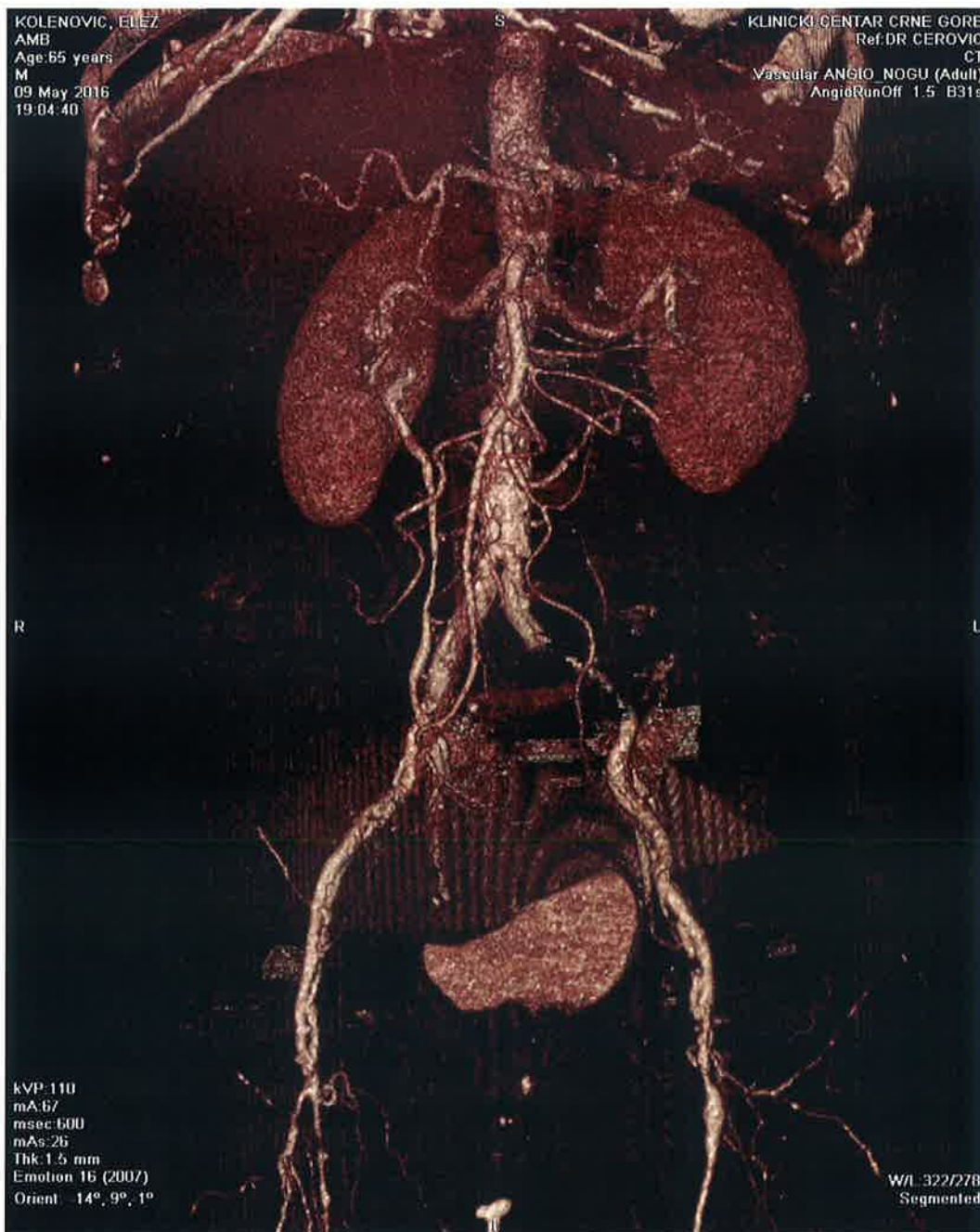
VITAL
The image of understanding

Patient ID: AMB
Patient Name:
KOLENOVIC^ELEZ
Date of Birth: 19510101
Gender: M

Referring Physician: DR CEROVIC
Exam Type: Vascular^ANGIO_NOGU
(Adult)
Scan Date: 20160509
Report Date: Monday, May 16, 2016
1:10:34 PM
Weight: Unspecified

Height: Unspecified

Institution Name
Street Address
City And State



Enter the general comments here.



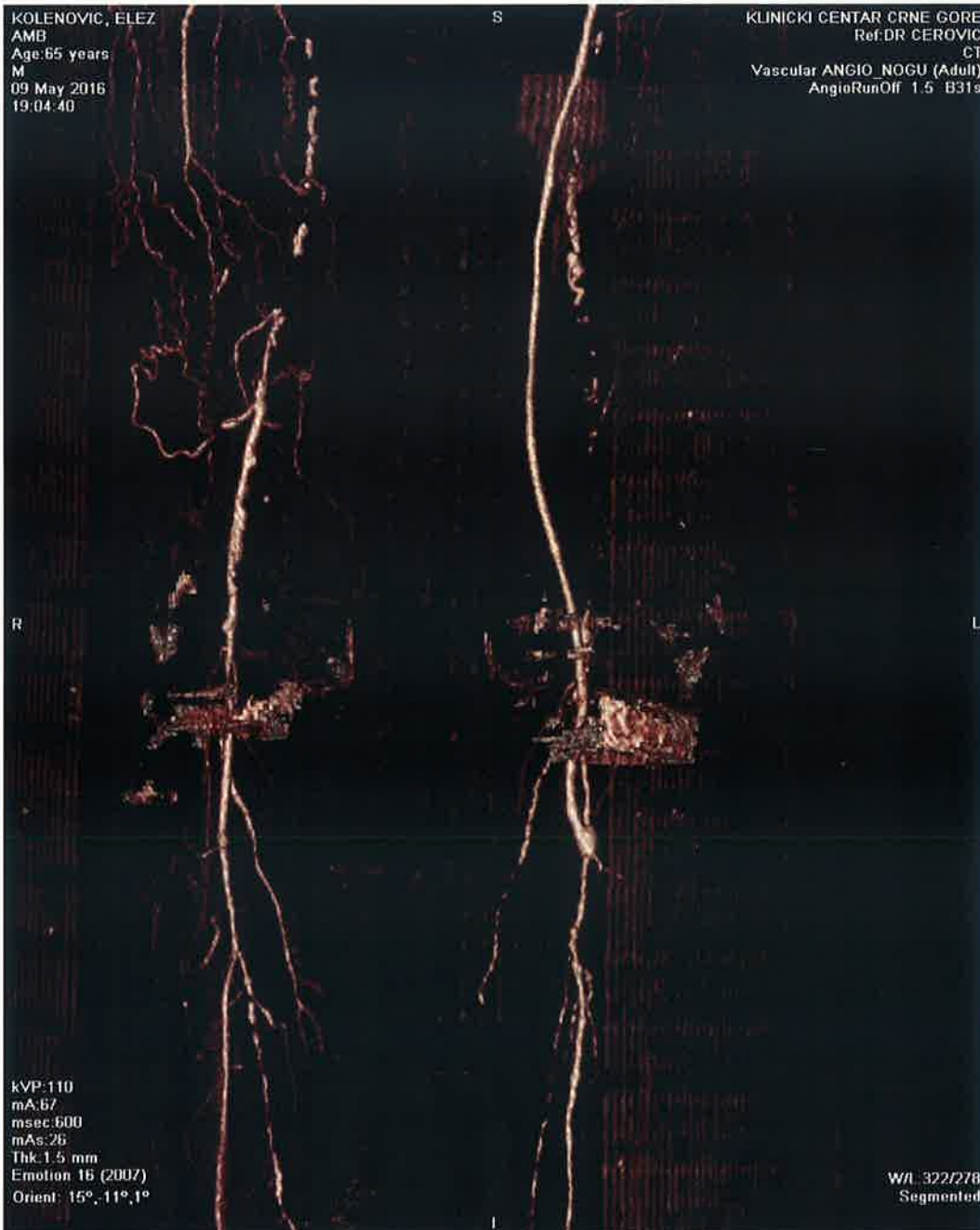
VITAL
The image of understanding

Patient ID: AMB
Patient Name:
KOLENOVIC^ELEZ
Date of Birth: 19510101
Gender: M

Referring Physician: DR CEROVIC
Exam Type: Vascular^ANGIO_NOGU
(Adult)
Scan Date: 20160509
Report Date: Monday, May 16, 2016
1:10:43 PM
Weight: Unspecified

Height: Unspecified

Institution Name
Street Address
City And State



Enter the general comments here.



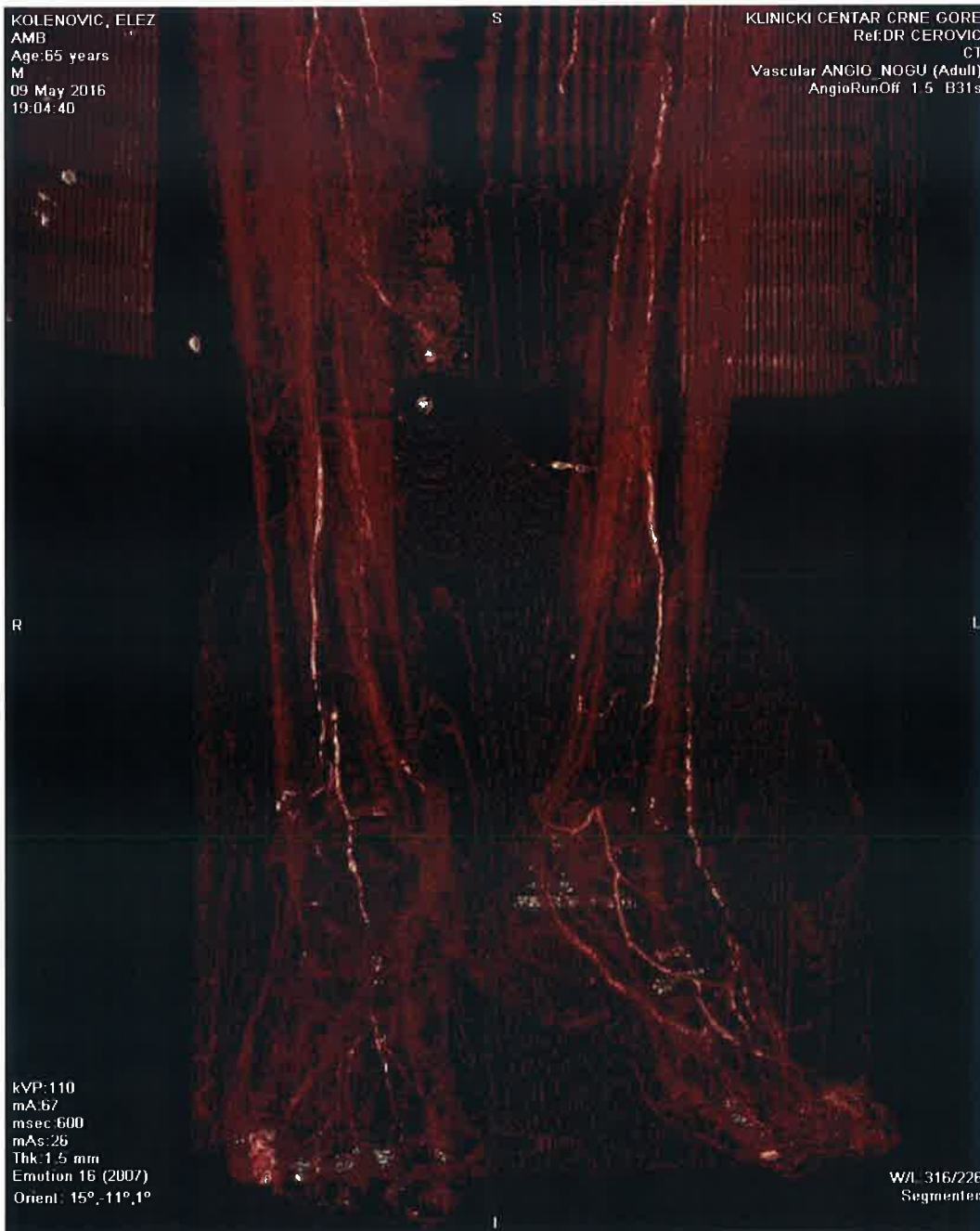
VITAL
The image of understanding

Institution Name
Street Address
City And State

Patient ID: AMB
Patient Name: KOLENOVIC^ELEZ
Date of Birth: 19510101
Gender: M

Height: Unspecified

Referring Physician: DR CEROVIC
Exam Type: Vascular^ANGIO_NOGU (Adult)
Scan Date: 20160509
Report Date: Monday, May 16, 2016 1:10:43 PM
Weight: Unspecified



Enter the general comments here.

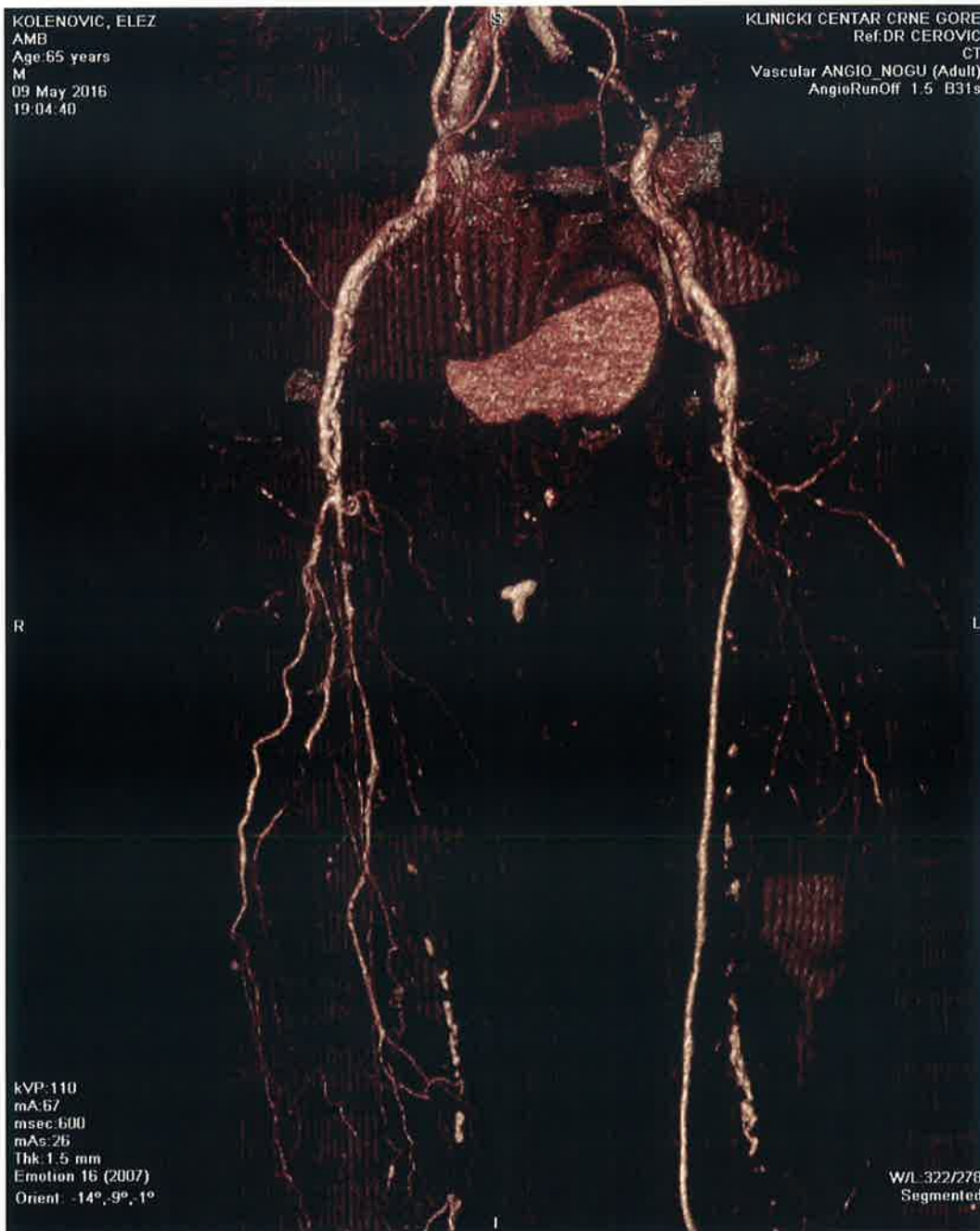

Institution Name
Street Address
City And State

Patient ID: AMB
Patient Name:
KOLENOVIC^ELEZ
Date of Birth: 19510101
Gender: M

Height: Unspecified

Referring Physician: DR CEROVIC
Exam Type: Vascular^ANGIO_NOGU
(Adult)
Scan Date: 20160509
Report Date: Monday, May 16, 2016
1:10:43 PM
Weight: Unspecified



Enter the general comments here.

Patient: KOLENOVIC^ELEZ Page: 8 of 8



VITAL
The image of understanding

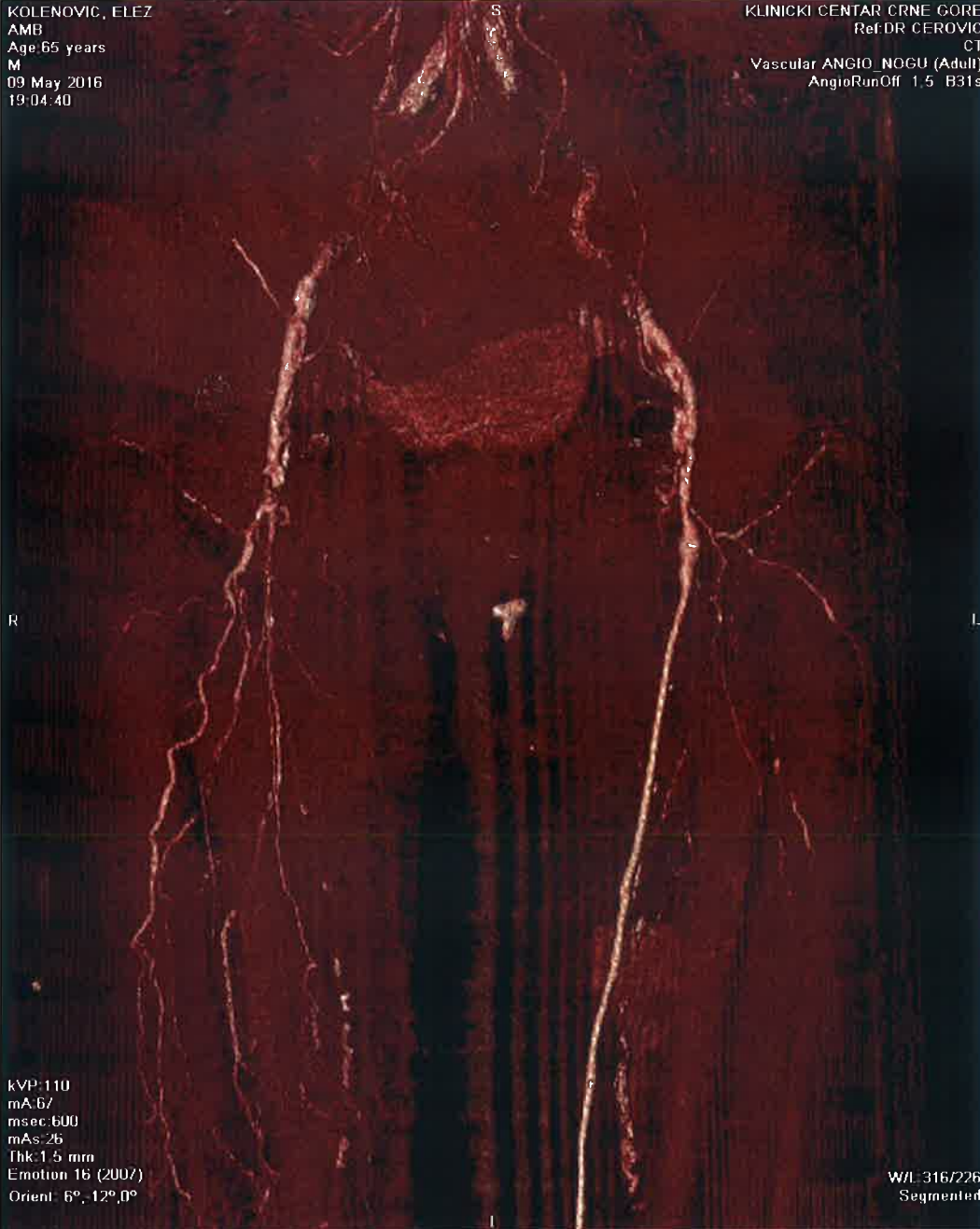Institution Name
Street Address
City And State

Patient ID: AMB
Patient Name: KOLENOVIC^ELEZ
Date of Birth: 19510101
Gender: M
Height: Unspecified

Referring Physician: DR CEROVIC
Exam Type: Vascular^ANGIO_NOGU (Adult)
Scan Date: 20160509
Report Date: Monday, May 16, 2016 1:10:43 PM
Weight: Unspecified

KOLENOVIC, ELEZ
AMB
Age 65 years
M
09 May 2016
19:04:40

KLINICKI CENTAR CRNE GORE
Ref: DR CEROVIC
CT
Vascular ANGIO_NOGU (Adult)
AngioRunOff 1.5 B31s



Enter the general comments here.



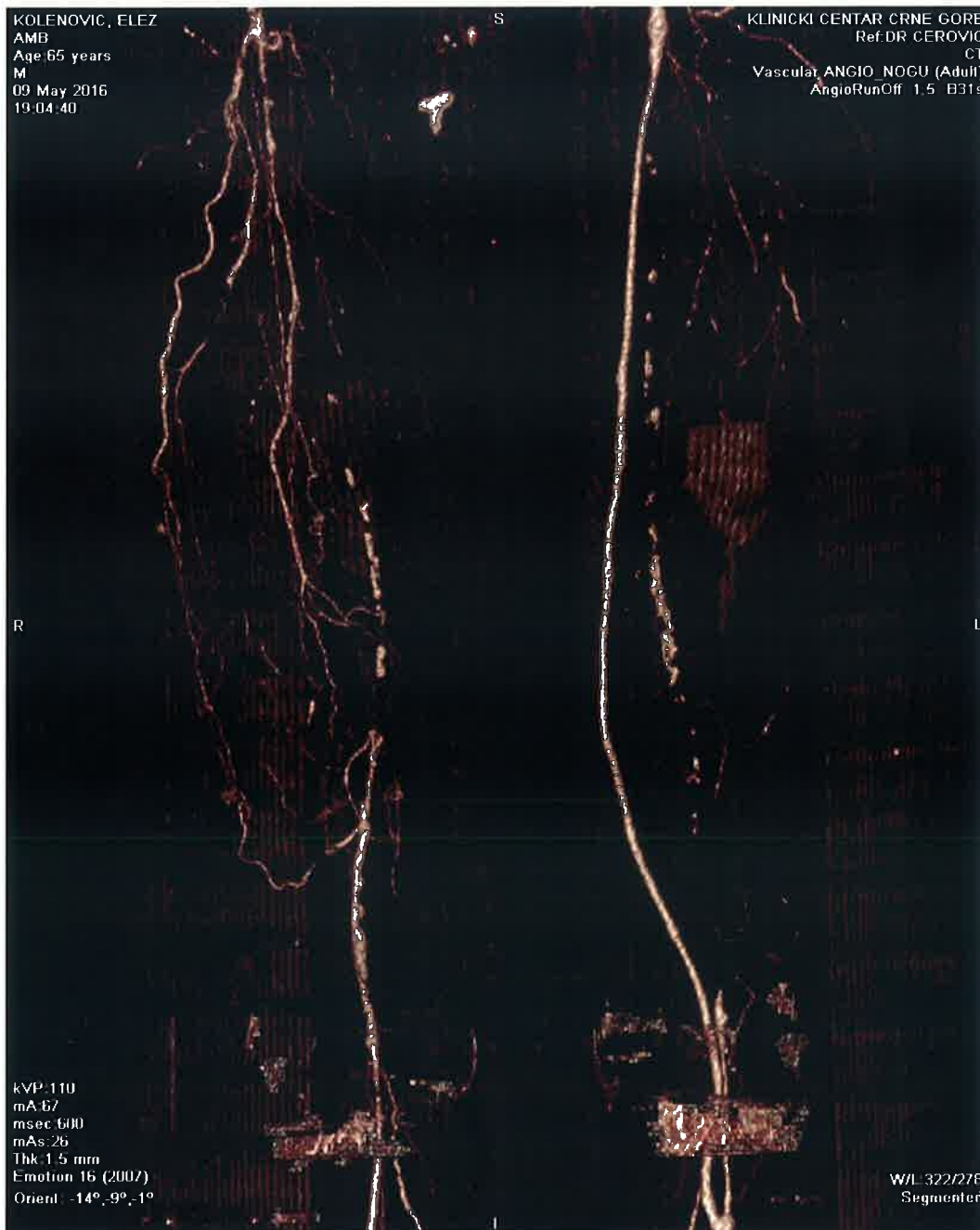
VITAL
The image of understanding

Institution Name
Street Address
City And State

Patient ID: AMB
Patient Name: KOLENOVIC^ELEZ
Date of Birth: 19510101
Gender: M

Height: Unspecified

Referring Physician: DR CEROVIC
Exam Type: Vascular^ANGIO_NOGU (Adult)
Scan Date: 20160509
Report Date: Monday, May 16, 2016 1:10:43 PM
Weight: Unspecified



Enter the general comments here.

**CRNOGORSKA
KOMERCIJALNA BANKA AD**



PODGORICA

Incoming Payment Instruction

Field 56 - Intermediary bank:

Swift Address	DEUTDEFF
Name	Deutsche Bank AG Frankfurt

Field 57 - Account with Institution:

Party Identifier	100 9363045 0000
Swift Address	CKBCMEPG
Name	CRNOGORSKA KOMERCIJALNA BANKA AD PODGORICA

Field 59 - Beneficiary Customer:

IBAN	ME25510200595127401038
Name & Address	Kolenovic A. Elez
	Ribnicka Vrela 4
	81000, Podgorica, MONTENEGRO

Kind regards,

Crnogorska Komercijalna banka AD Podgorica
International Payment Department